



**PATIENT**

Oso Hood

**PRESENTING CLINICAL SIGNS**

History: Heart murmur. Assess prior to dental.

**SPECIES**

Canine

**ELECTROCARDIOGRAPHIC FINDINGS** \*Note: Single lead ECGs are evaluated as a rhythm strip.

Morphology/MEA cannot be definitively commented on.

A single lead ECG is available; 50mm/s, 20mm/mV. The average heart rate is 85bpm (range 75-94bpm). The rhythm is sinus in origin, with a p for every QRS complex and vice versa. The P and QRS morphologies are positive. No ectopic beats, pauses or other dysrhythmias observed.

**BREED**

Husky

ECG diagnosis: Normal sinus rhythm with respiratory variation.

**SEX**

Male Neutered

**ECHOCARDIOGRAM FINDINGS**

2D, m-mode, color flow and doppler imaging is available. Minimal diffuse thickening of mitral valve leaflets with no obvious prolapse into the left atrial lumen. No mitral regurgitation is identified. Normal left atrial dimension. Normal LV diameter with adequate myocardial function. The tricuspid valve appears subjectively normal, with no tricuspid regurgitation. The right heart is normal (subjective). No overt evidence of pulmonary arterial hypertension. The pulmonic and aortic valves are normal in morphology and mobility. No aortic abnormalities identified, however the LVOT velocity is borderline elevated. Normal pulmonic outflow velocities. No aortic or pulmonic insufficiency. No pericardial or pleural effusion noted. No cardiac tumors observed.

**AGE**

2 years

**CARDIAC CHART**

**WEIGHT**

48lbs

**INTERPRETED BY**

Maggie Machen Lamy,  
DVM, DACVIM  
(Cardiology)

CANINE CARDIAC PARAMETERS	MR VMAX (m/s)	TR VMAX (m/s)	LA/AO (Boon method)	LA/AO (Heart Base; Swe)	FS (%)	EF (%)	EPSS (cm)
<b>NORMAL PARAMETER</b>	4.5-5.5	<2.7	1.3	<1.6	28-40	40-100	<0.6
<b>PATIENT</b>	NA	NA	NM	1.2	31	60	NM
CANINE CARDIAC PARAMETERS	HR (BPM)	AV VMAX (m/s)	PV MAX (m/s)	BODY WEIGHT (kg)	LA 2D short axis Base view (cm)	LVIDd Avg; 2D and m-mode short axis (cm)	LVIDs Avg; 2D and m-mode short axis (cm)
<b>NORMAL PARAMETER</b>	50-100	0.7-1.7	0.7-1.6	BELOW	BELOW	BELOW	BELOW
<b>PATIENT</b>	NM	1.7	1.4	21.8	2.3	3.5	2.3
*Normal chamber parameters expressed as a mean value (SD)							
<b>BODY WEIGHT DEPENDENT PARAMETERS</b>							
<i>*Note: All measurements based upon multi-modal images and methods. An average value is reported.</i>							
	3	1.27 (5.3)	2.46 (2.46)	1.36 (5.5)	5	1.40 (4.5)	2.74 (5.2)
	10	1.50 (3.8)	3.27 (3.5)	2.06 (3.1)	15	1.83 (2.0)	3.71 (2.4)
	20	2.02 (1.9)	4.14 (2.2)	2.80 (2.0)	25	2.18 (2.4)	4.48 (2.9)
	30	2.33 (3.3)	4.83 (3.9)	3.39 (3.4)	35	2.48 (4.3)	5.17 (5.0)
	40	2.62 (5.2)	5.48 (6.1)	3.96 (5.4)	50	2.88 (7.1)	6.07 (8.3)
	50	2.88 (7.1)	6.07 (8.3)	4.46 (7.4)			

Adapted from June Boon, Veterinary Echocardiography, 1998  
Rishniw M and Hollis NE, J Vet Intern Med 2000; 14:429-435  
Hansson et al, Vet Rad and Ultrasound 2002  
Bonagura et al. Echocardiography: principles of interpretation, Vet Clin North Am 15:1177, 1995

**IMAGING PERFORMED BY**

Dana Alterman,  
RDCE, LVT

**HOSPITAL NAME**

Eubank Animal Clinic

**REFERRING VET**

Dr. Solan

**INVOICE**

28495

**DATE**

1/23/23

**INTERPRETATION OF THE FINDINGS & FURTHER RECOMMENDATIONS**

The only cause of a murmur identified is borderline increased flow velocity through the LVOT/aortic root. No obvious subaortic ridge or valvular abnormalities are visualized, and in the absence of structural abnormalities this is considered a benign flow murmur. If this is a new



**PATIENT**

Oso Hood

murmur, it is reasonable to monitor periodically via recheck echocardiography in the future. Additionally screening for fluid status abnormalities (dehydration, anemia, etc.) is recommended through routine lab work as these abnormalities would make this finding more prevalent. No significant valvular insufficiencies were noted and no structural issues identified.

**SPECIES**

Canine

No cardiac medications are indicated. No cardiac contraindication for general anesthesia.

**BREED**

Husky

Monitor for any development of cough, labored breathing or exercise intolerance.

**SEX**

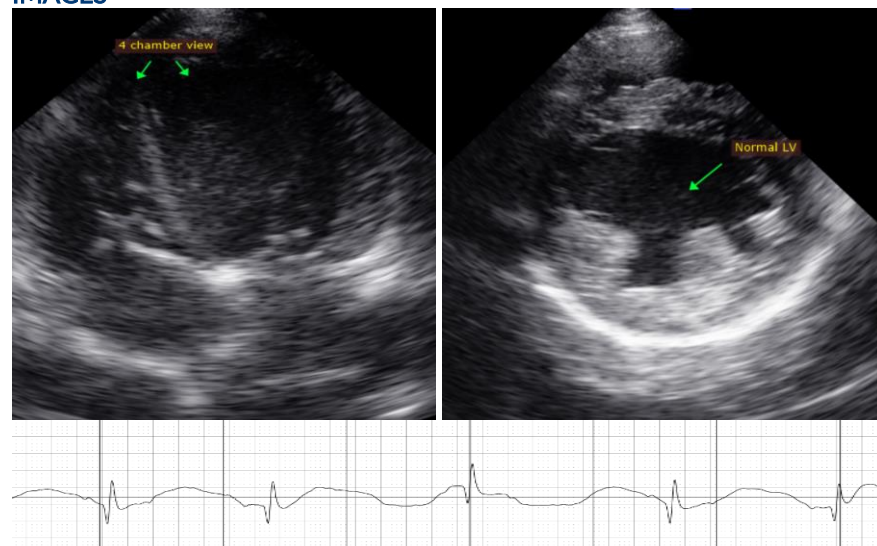
Male Neutered

Recommend recheck echocardiogram in 12-18 months to screen for progression or development of concurrent cardiac disease that the preexisting murmur may mask.

**AGE**

2 years

**IMAGES**



**WEIGHT**

48lbs

**INTERPRETED BY**

Maggie Machen Lamy,  
DVM, DACVIM  
(Cardiology)

The information and recommendations provided are based on the images presented by the referring veterinarian. No evaluation can be communicated regarding pathology that was not visible in the image/video clips provided.

**IMAGING PERFORMED BY**

Dana Alterman,  
RDCS, LVT

Thank you for this referral. This report was generated using transcription software, and minor dictation errors may be present. If the clinical or image interpretation does not parallel your findings or if I can be of any further assistance, please contact me.

**HOSPITAL NAME**

Eubank Animal Clinic

**REFERRING VET**

Dr. Solan

Maggie Machen Lamy, DVM  
Diplomate of the American College of Veterinary Internal Medicine (Cardiology)  
info@sonopath.com

**INVOICE**

28495

**DATE**

1/23/23



**PATIENT**

Oso Hood

**SPECIES**

Canine

**BREED**

Husky

**SEX**

Male Neutered

**AGE**

2 years

**WEIGHT**

48lbs

**INTERPRETED BY**

Maggie Machen Lamy,  
DVM, DACVIM  
(Cardiology)

**IMAGING  
PERFORMED BY**

Dana Alterman,  
RDCS, LVT

**HOSPITAL NAME**

Eubank Animal Clinic

**REFERRING VET**

Dr. Solan

**INVOICE**

28495

**DATE**

1/23/23